

6. Some Notes upon *Boa occidentalis* and *Boa (Pelophilus) madagascariensis*. By FRANK E. BEDDARD, M.A., F.R.S., F.Z.S., Prosector to the Society.

[Received October 26, 1909.]

(Text-figures 281–285.)

In a series of papers recently communicated to this Society, to which I shall refer in the course of the present communication, I have dealt with a number of points in the anatomy of certain snakes of the family Boidæ belonging to the following species:—*Eunectes murinus*, *E. notæus*, *Boa constrictor*, *B. diviniiloqua*, *Eryx conicus*, *E. jaculus*, *E. johni*, *Corallus cookii*, *C. madagascariensis*, *C. caninus*, *Python spilotes*, *P. sebec*, *P. molurus*, *P. regius*, *Enygrus carinatus*.

I have, recently had the opportunity of examining a specimen apiece of the two species of *Boa*, *B. occidentalis* and *B. madagascariensis*. The latter species has been referred to a genus *Pelophilus*, and it is one of the species of *Boa* which occurs in Madagascar. The distribution of this genus *Boa* is exactly paralleled by the distribution of the allied genus *Corallus*. For in both the majority of the species are Neotropical in range, while one or two are confined to the island of Madagascar. It is therefore of particular interest to be able to compare the characteristics of the Madagascar *Boa* with those of its Neotropical allies, and to set side by side the facts thus obtained with those resulting from the anatomical study of the Madagascar and Neotropical species of *Corallus*. To some extent I am able, in the present communication, to accomplish this comparison; but various reasons prevented me from being able to give so complete an account of the facts as might be desired in the two species. I can, however, direct attention to the more important among these. I shall deal with them in a comparative fashion, describing the conditions of the lungs and certain blood-vessels in the two species.

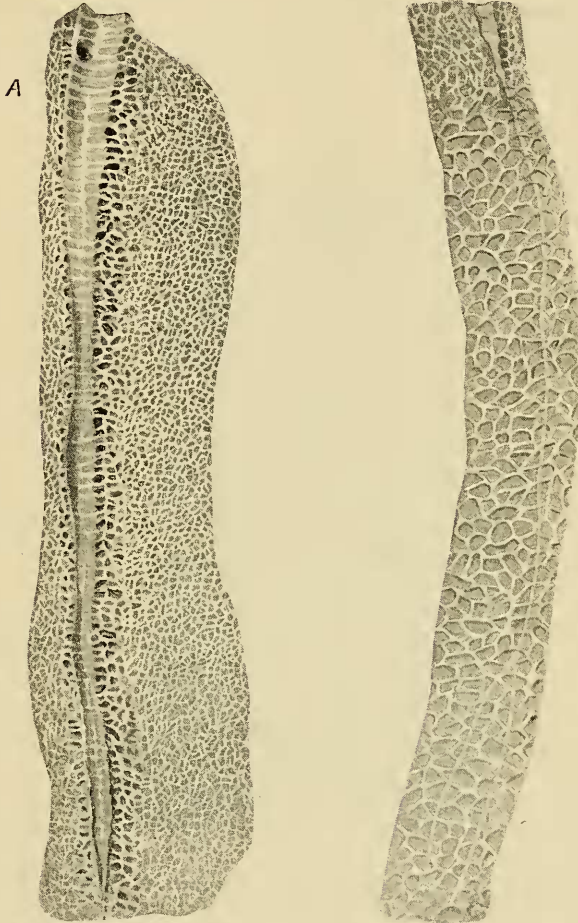
#### § Lungs.

In *Boa occidentalis* the conditions of the two lungs differed somewhat, as is the rule among these serpents. Not only are the two lungs unequal in size, as is universal (?) among those Boidæ (the vast majority) which possess two lungs, but the windpipe divides into two bronchi, which are unlike in the case of the right and the left lung. In this species the bronchus of the smaller lung projects but a short way into its interior as a flattened plate; its length was at most half an inch. At its extremity the bronchus did not tail off into a seam running along the lung substance such as occurs, as will be mentioned presently, in the other lung. Its condition can be contrasted

with that of the larger lung, which is represented in the drawing exhibited herewith (text-fig. 281). The bronchial gutter of the

Text-fig. 281.

Text-fig. 282.



Text-fig. 281.—Interior of anterior half of larger lung of *Boa occidentalis*, showing bronchial gutter within lung.

A. Orifice of bronchus of other lung.

Text-fig. 282.—A portion of the larger lung of *Boa occidentalis* immediately following that illustrated in text-fig. 281. The end of the bronchial gutter is shown and the "seam" continuous with it, which bifurcates distally.

larger lung extends along that lung for fully seven inches, the disproportion between the two lungs in this respect being therefore

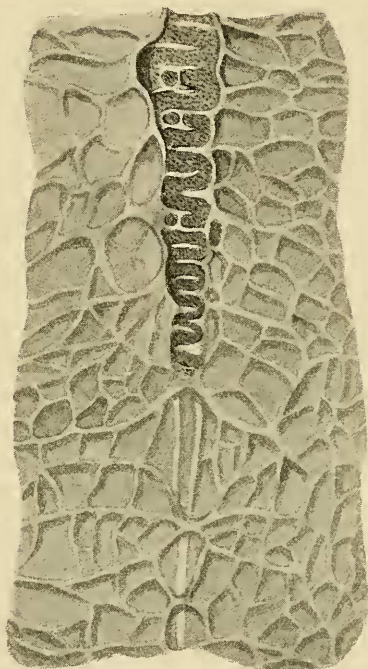
enormous and bearing no possible relation to their relative size, for the larger lung is at most twice the size of the smaller. At its extremity the bronchial gutter narrows to almost thread-like proportions. There was no trace that I could discover of a condition like that of *Corallus caninus*\*, where the semirings become irregular in position and leave tracts of lung substance between them. The bronchus was perfectly continuous as such up to its very end. It is furthermore to be noted that the gutter-like character of the imperfect bronchus is very marked here. I should imagine, indeed, that it may become functionally a tube within the lung under certain conditions. Under such circumstances the rapid distention of the terminal anangious region of the lung might be effected, for terrifying or other purposes. As in some other snakes, of which particular mention will be made presently, *Boa occidentalis* shows a seam running a considerable distance along the lung which starts from the termination of the bronchus in the larger lung. As is to be seen from an inspection of the accompanying figure (text-fig. 283), this seam appears to be quite independent of the partitions between the alveoli of the lung. It is evidently a structure distinct from them, for in some cases it crosses a definite alveolus at the middle. The seam is, in fact, not merely the coalescence of the walls of a series of alveoli. This fact (*i. e.* that it is an independent structure) seems to show that the view generally held as to the nature of this seam, namely that it is a rudiment of the bronchus, is the correct view. The seam extends far into the anangious region of the lung, and, as already mentioned, it is only in this larger lung that it occurs, being absent in the smaller.

This seam extends for a distance down the lung which is fully as great as the length of the bronchial gutter. Its diameter is about as great as that of the stouter alveolar walls. But this fact does not permit of any confusion between the structures, nor hinders the accurate tracing of the course of the bronchial seam. For the latter is of a distinctly white colour as compared with the brown colour of the inner surface of the lungs including the walls of the alveoli—due to the formalin in which the lung was preserved. Another reason which leads to the easy identification of this fibrous seam throughout its whole course has already been briefly mentioned. The seam appears to cross over the lung alveoli, and is thus evidently not composed of a series of coincident alveolar walls. But more than this can be observed in its relations to the alveolar walls. It will be seen from an inspection of the accompanying figure (text-fig. 283) that the seam does not fuse with the alveolar walls but passes above them, and is indeed quite independent of them. All this of course establishes on a very firm basis the view that this seam is a real continuation of the bronchus as it appears to be. It has already been mentioned that in the smaller lung there is no trace

\* "A Comparison of the Neotropical Species of *Corallus*, &c.," P. Z. S. 1908, p. 135; see text-fig. 27, p. 156.

of any such seam; the bronchus in this lung ends abruptly, and there is no diminution towards or at the end in the calibre of its semirings. On the other hand, in the larger lung the cartilages, though continuing to the end of the intrapulmonary bronchus, get successively narrower and narrower. I have not observed in other Boas and Pythons where a fibrous continuation of the intrapulmonary bronchus occurs, any suggestion of a branching of this seam, which I now proceed to describe in *Boa occidentalis*.

Text-fig. 283.



A

A magnified representation of the end of the bronchial gutter in the same lung as shown in text-figs. 281 & 282, to show the double origin of the seam and its independence from the walls of the pulmonary alveoli.

At a considerable distance behind the termination of the intrapulmonary bronchus the seam gives off a branch (see text-fig. 282, p. 919) which runs obliquely towards that wall of the lung which is contiguous with the wall of the smaller lung. This seam is no smaller than the main seam, of which it is a branch, and shows the same characters that have been enumerated above. It ends by bifurcating into two branches.

This fact appears to me to be of the most interesting

significance. If it be admitted that the fibrous seam connected with the bronchus is the degenerate equivalent of a further extension into the lung of the bronchus, it follows that the branching of this seam is a trace of a former branching within the lung of the bronchus. In fact, that we have in the snake's lung evidence of a reduction to its present simplicity from a lung more like that of a Tortoise or Crocodile, or—and this comparison may be better—a *Varanus*. For in these latter types the intrapulmonary region of the bronchus is branched or shows traces of branching. In this case the simple character of the lung of the Boidæ is not to be strictly compared with the simple sac-like lung of, e. g., *Hatteria*. For the latter exhibits, as I believe, a primitive state of affairs, and is not much more evolved than the lung of an Amphibian, while the former may have returned to the simple condition through degradation.

We may now contrast the structure of the lung in *Boa occidentalis* with that of *B. madagascariensis*. In the latter species each bronchus enters its lung, and there is thus, as in *B. occidentalis*, an intrapulmonary bronchus. But the intrapulmonary bronchus is very short in the case of both lungs, though the larger lung has a rather longer intrapulmonary bronchus. I found that the measurements were seven eighths of an inch in the case of the larger lung and three eighths in the case of the smaller lung: thus the intrapulmonary bronchus was in the larger lung about double the length of that of the smaller lung. It is clear, therefore, that there is here a very great difference both actually and proportionately (as concerns the two lungs), between the Madagascar species and the Neotropical species which are considered in the present communication. Furthermore, there is not a marked seam continuing down the bronchus in the case of either lung. There appears to be one; but when the lung tissue is stretched the seam disappears. This is analogous to what I have described in *Corallus*. We have therefore a second important difference in the structure of the lungs between *Boa occidentalis* and its Madagascar ally.

I have already described or confirmed the description of the intrapulmonary bronchi of the two American species\* *Boa constrictor* and *B. divinitoqua*. In both of these the bronchus extends a long way down into the interior of the larger lung exactly as I have just shown to be the case in *B. occidentalis*. With regard to the extension of the bronchus into the smaller lung, it would appear that *Boa occidentalis* occupies a position exactly intermediate between the two other species. For in *B. divinitoqua* the bronchus extends for a goodish way into this lung, while in *Boa constrictor* there is no intrapulmonary bronchus at all within the smaller lung. In any case there is a general agreement between the three Neotropical species of *Boa* dealt with in the present communication, and a difference

\* P. Z. S. 1906, p. 516.



between all of them and the Madagascar species. It is interesting to note that while the corresponding species of *Corallus* also differ in the structure of the lungs, the difference is of precisely the reverse kind to that which we find in *Boa*. For in *Corallus* it is the Madagascar species \* which possesses the long intrapulmonary bronchus and the Neotropical forms which have a short intrapulmonary bronchus.

### § *Aorta and Intercostal Arteries.*

The great variations which the system of intercostal arteries shows among Serpents as contrasted with the Lacertilia is a remarkable fact in the anatomy of the former order of Reptiles, and is one of the many anatomical facts which prove their comparative remoteness in affinity from the Lizards. Moreover, the condition of these arteries appears to be quite constant for a species, and even for groups of species, though the current generic divisions among the Boidæ are not in entire harmony with the arrangement of the intercostal arteries. In a series of papers † dealing with these and other points in the anatomy of the Boidæ, I have got together a considerable number of facts relative to the distribution of the intercostal arteries in those serpents.

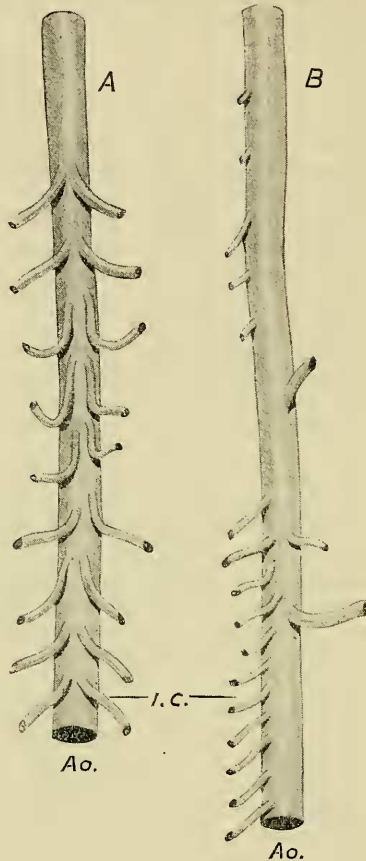
I have in the present paper some new facts to add to those already collected, which I shall describe before considering the classificatory results which appear to follow from a comparison of the actual facts with those already known. In *Boa occidentalis* the aorta in the region of the liver is by no means nearly in contact with the dorsal parietes. It lies at some distance within the body from the dorsal middle line of the body. It is possible that this fact of position has something to do with the differing arrangement of the intercostal arteries shown in this region of the body as compared with the posterior region of the body of the serpent. In any case, in the hepatic region the intercostal arteries arise singly and at considerable intervals from the ventral surface of the aorta. There are altogether very few of them. They become connected at a short distance from the dorsal middle line with smaller trunks running fore and aft in close relation to the middle line of the body. From these secondary longitudinal arteries arise in regular pairs the actual intercostal twigs. In the abdominal region of the body, as it may be termed, near to the kidneys, the intercostal arteries are different in their arrangement.

\* P. Z. S. 1908, p. 151.

† "Contributions to our Knowledge of the Circulatory System of the Ophidia," P. Z. S. 1904, vol. i. p. 331. "Notes upon the Anatomy of certain Snakes of the Family Boidæ," P. Z. S. 1904, vol. ii. p. 107. "Contributions to the Knowledge of the Vascular and Respiratory Systems in the Ophidia and to the Anatomy of the Genera *Boa* and *Corallus*," P. Z. S. 1906, p. 499. "A Comparison of the Neotropical Species of *Corallus*, *C. cookii*, with *C. madagascariensis*, and on some points in the Anatomy of *Corallus caninus*," P. Z. S. 1908, p. 135.

Here there is no development of a series of secondary longitudinal trunks. The aorta itself is in close apposition to the dorsal middle line. And the intercostal branches arise in regular pairs,

Text-fig. 284.



Two isolated pieces of the dorsal aorta of *Boa madagascariensis*.

A. From the region of the kidney. B. From the region of the liver.

Ao. Aorta. i.c. Intercostal arteries.

The arteries shown to the right of B are hepatic or gastric arteries.

one pair to each vertebra, from the aorta itself. The development of secondary longitudinal trunks, which is so common a phenomenon in veins and arteries among the Ophidia, is, however, seen

in this region of the body, though not in any way comparable to the secondary longitudinal trunks already described in the more anterior region of the body. Laterally, and here and there, there are slender longitudinal arteries connecting a successive series of intercostals at some distance from their origin from the aorta. This, it will be seen, is quite a different thing to the conditions described in the more anterior region of the body where the longitudinal trunks occur before the intercostals are given off. This, then, is the state of affairs which the intercostal arteries of *Boa occidentalis* show. In the Madagascar species the intercostals are different in their origin anteriorly. In the liver region of the body the intercostals arise regularly from the aorta itself, and vary as to whether they arise actually in pairs or from a single branch which shortly divides in a Y-like fashion to form the intercostal of each side. This is shown in the accompanying figure (text-fig. 284), which represents a piece of the aorta in the anterior region of the body. In the kidney region the intercostals are also given off in regular pairs from the aorta itself, and are paired from the very first. Thus *Boa madagascariensis* agrees with *B. occidentalis* in the origin of the more posteriorly situated set of intercostals, but differs in the origin of the more anteriorly situated set. We find, therefore, that in the intercostal arteries, as in the structure of the lungs, the Madagascar species of *Boa* differs from the Neotropical *Boa occidentalis*. It is furthermore important to note that the Neotropical species of *Boa* described in the present paper agrees in the points just raised with the other two Neotropical species, viz., *B. divinitoqua* and *B. constrictor*. A difference in geographical position thus corresponds with certain definite structural differences. Finally, it is not without interest to observe that there is a very close parallel between the New World and Old World Boas on the one hand, and the New World and Old World *Corallus* on the other hand.

The parallel, moreover, is more exact than that which can be drawn in the case of the lung. For the difference in the intercostal vessels between the Boas of the Neotropical region and that of Madagascar is quite the same as that between the two Neotropical species of *Corallus* which have been studied and their Madagascar representative. I have already described the latter facts in some detail\*, and refer to my description. Had the parallel in the structure of the lungs been as close as that which the arterial system shows, it might have been permissible to consider the question whether the Madagascar Boines of both genera were not better included in the same genus. At present, however, this alteration of existing views seems to me to be premature.

\* "A Comparison of the Neotropical Species of *Corallus*, &c.," P. Z. S. 1908, p. 135.



### § *Renal Arteries.*

In the series of papers dealing with the anatomy of the Boidæ, to which I have referred in the course of the present communication, I have many times mentioned the fact that among the Boidæ the existence of but a single artery to each kidney is the rule, with but slight exceptions.

It may now be safely asserted that this diminution in the number of the renal arteries, which never exceed two to each kidney, and that only in the genus *Eryx*, is a characteristic of the group. *Boa occidentalis* is no exception to this rule, and I found in the case of one kidney but one renal artery, which was followed carefully from its origin from the aorta down to the end of the kidney, which it first touches at the anterior end of that viscus. In the case of the other kidney, it seemed to me (and though I am not quite positive as to the fact, I am very nearly sure) that the single renal artery arose not independently from the aorta, but as a branch of one of the intestinal arteries. Unfortunately, the condition of the renal arteries is one of the points which I did not ascertain in the species *Boa madagascariensis*.

### § *Alimentary Viscera.*

There is frequently an inequality between the two lobes of the liver in Serpents, and among them in the Boidæ. Up to the present, I believe that the most marked case of inequality in length between these two lobes occurs in *Corallus madagascariensis*, where I have described it.

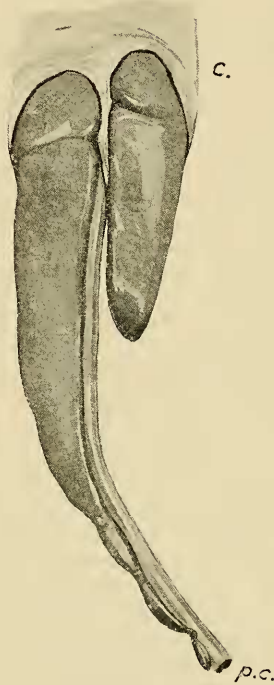In that snake\* the long thin "tail" of the liver was some four inches long. I have now to record the same kind of inequality in *Boa occidentalis*, where, however, it is not so marked as in the species of *Corallus*, but still very striking. In the example of *Boa occidentalis* which I dissected, the "tail" measured about 3 inches, as is shown in the accompanying figure (text-fig. 285). The *stomach* of the same snake, which was in a contracted condition, showed on each side a very marked tænia.

It is well known that the *small intestine* of snakes is the only region of the gut which is folded, the rest of the alimentary canal being straight. As a contribution to our knowledge of the extent to which this folding takes place, I made some measurements of the small intestine of *Boa madagascariensis*. In this snake the coiled small intestine lay between the pancreas and the region of the testis. It measured no less than 31 inches. The length of the body of the reptile between the points which lodged this coiled gut was only 4 or 5 inches. I did not make a corresponding observation upon *Boa occidentalis*.

\* "Contributions to the Knowledge of the Vascular and Respiratory Systems in the Ophidia, &c.," P. Z. S. 1906, p. 517.

There is some variation among the Boine Snakes in the arrangement of the pancreas and spleen\*. It is, therefore, desirable to record the conditions that I have found in *Boa occidentalis*. I find in that snake that the large rounded pancreas which lies in connection with the duodenal wall is connected with the spleen by an isthmus of pancreatic tissue not of very great

Text-fig. 285.

End of liver of *Boa occidentalis*.

c. Celomic sac of liver partly removed. p.c. Postcardinal vein.

length, but slender and widening out at its contact with the spleen. The latter organ is lobate, and in consequence somewhat mulberry-like in contour. I have no observations concerning these various glands in *Boa madagascariensis*.

\* For a summary of the facts see my paper upon *Corallus* already quoted in P. Z. S. 1908, p. 147.